

A Review on the Characteristics and Indications of Mineral Trioxide Aggregate (MTA) for its Use in Endodontics

Sukumar S., Dřížhal I., Bednář P.

Dental clinic of the Faculty of Medicine, Charles University
And Faculty Teaching Hospital in Hradec Králové.

Summary

Mineral Trioxide Aggregate (MTA) was introduced into dentistry as a root-end filling material. Several researches and investigations were done on its properties and uses. In this review, the composition, properties and indications of MTA are mentioned, along with the techniques for its use in various clinical situations like pulp capping, internal and external root resorptions, lateral and strip perforations, furcal perforation, apexification, root-end filling and root-canal filling. A case report of repairing furcal perforation using MTA is also documented.

Key words: Mineral Trioxide Aggregate (MTA) – root canal treatment (RCT) – furcal perforation – lateral and strip perforations – pulp capping.

Sukumar S., Dřížhal I., Bednář P.:

Charakteristické údaje pro využití Mineralu Trioxide Aggregate (MTA) ve stomatologické praxi

Souhrn: Mineral Trioxide Aggregate (MTA) byl uveden do stomatologie jako vyplňový materiál pro apex zubního kořene. Řada výzkumů, sledování jeho vlastností a poznatků z jeho aplikací byla publikována. V předloženém přehledném článku autoři shrnují tyto zkušenosti, uvádějí i techniku použití, včetně osvědčených postupů u různých typů poškození, jako přímé překrytí pulpy, vnitřní a vnější resorpce kořene, uzavření perforací kořene, perforace ve furkaci, u apexifikace a při jeho použití jako kořenové výplně. Autoři také demonstují jeden případ úspěšně ošetření perforace ve furkaci s použitím tohoto preparátu.

Klíčová slova: Mineral Trioxide Aggregate (MTA) – ošetření kořenového kanálku – perforace ve furkaci – via falsa v kořenovém průduchu – přímé překrytí pulpy

Prakt. zub. Lék., roč. 55, 2007, č. 3, s. 43–47.

INTRODUCTION

The sophistication of endodontic techniques and introduction of new dental materials are contributing largely to the overall success of endodontic treatment outcomes. Mineral trioxide aggregate (MTA) is a relatively new material which was introduced into dentistry as a root end filling material. It has a lot of implications in modern day dentistry. MTA was developed by Dr. Mahmoud Torabinejad at the Loma Linda university in 1993 [22]. It has been used on an experimental basis by endodontists since then with anecdotally reported success, some of it quite impressive.

Materials such as zinc oxide-eugenol cement and resin composite have been used in the past to repair root defects, but their use resulted in the

formation of fibrous connective tissue adjacent to the bone. Other commonly used materials such as amalgam, glass-ionomer and calcium hydroxide are also not ideal for special conditions and requirements of root repair. Because it allows the overgrowth of cementum and periodontal ligament, MTA may be an ideal material for certain endodontic procedures. MTA's approval in 1998 by the U.S. Food and Drug Administration should lead to more widespread use [16].

COMPOSITION AND MANIPULATION

MTA is a cement mainly composed of :

1. Tricalcium silicate
2. Dicalcium silicate

3. Tricalcium aluminate
4. Tetracalcium aluminoferrite
5. Calcium sulfate
6. Bismuth oxide [13]

MTA is identical to Portlands cement except for the addition of bismuth oxide. Bismuth oxide is believed to modify its setting properties and also renders radio-opacity [13, 3].

MTA can be of two types-white and gray. The basic difference between the two is that the gray type contains more concentrations of metal oxides like bismuth oxide, ferric oxide and aluminium oxide [3].

The material is mixed with sterile water or saline or anesthetic solution to become a sandy mixture. It can be carried with the help of a Dovgan carrier or a Messing gun. MTA is hydrophilic and so requires moisture for setting. It has low solubility and takes an average of 3-4 hours for the material to completely solidify. Once solidified, it becomes very hard [13].

PROPERTIES

1. Compressive strength of MTA is equal to that of other retro filling materials like intermediate restorative material (IRM) and ethoxy benzoic acid (Super EBA), but less than that of amalgam [19].
2. MTA has an alkaline pH of 12.5 after 3 hours of setting which gradually decreases with time [19].
3. Sets only in the presence of moisture [13].
4. Biocompatible to oral tissues [11].
5. Non-toxic and non-resorbable [13].
6. Promotes healing, induce cementogenesis and bone deposition [5] and also enhances reparative dentin formation [21].
7. Bacteriostatic [20].
8. Radio-opaque [19].
9. Marginal adaptation and sealing ability [4].

INDICATIONS

Because of its amazing properties MTA can be used for a variety of cases. It is already proven that MTA is beneficial for clinical situations like:

1. Pulp capping
2. Internal and external root resorption
3. Lateral and strip perforations
4. Furcation perforation
5. Apexification
6. Root-end filling
7. Root canal filling [6, 4, 13]

1. Pulp capping

Direct pulp capping is indicated for teeth with immature apices [14] when the dental pulp is exposed with no signs of irreversible pulpitis and also for teeth with mature apices when there is an accidental or iatrogenic exposure of pulp. Pulp capping with MTA results in higher incidence and faster rate of reparative dentin formation, than with calcium hydroxide [21]. MTA also provides a better seal against bacteria.

Technique: Achieve proper anesthesia. Isolate with rubber dam. Then the exposed pulp and the cavity should be irrigated with sodium hypochlorite to control bleeding and to remove any remaining debris. Mix MTA powder with sterile water or saline and place the mixture in contact with the exposure using a Dovgan carrier. Compress the mixture against the exposure site with a moist cotton pellet. Remove the excess and place a moist cotton pellet over the MTA and fill the rest of the cavity with a temporary filling material. After 4 hours see the patient again, place rubber dam and remove temporary filling and cotton pellet. Assess the set of MTA and then restore the tooth with amalgam or composite [22].

2. Internal and external root resorptions

Internal root resorption: Due to its ability to induce cementogenesis, MTA can be used to treat internal as well as external root resorptions. In case of internal root resorption, the technique is as follows:- perform root canal treatment (RCT) in the usual manner. Once the cleaning and shaping of canals are over, mix MTA with sterile water or saline. Then fill the canal with the MTA using an endodontic plugger or gutta percha cone. Next, using a spreader, spread the cement laterally to cover the defect and create a new canal. Flood the canal with an epoxy resin cement and obturate it with a single gutta percha cone. The MTA will replace the resorbed tooth structure, thereby providing structure and strength to the tooth.

External root resorption: In this case, RCT is completed first. Next raise a flap and remove the defect on the root surface with a slow speed round bur. Mix MTA with saline or sterile water and apply it to root surface. Remove the excess cement and condition the surface with tetracycline. Then graft the bony defect with decalcified freeze-dried bone allograft and a calcium sulfate barrier [22]

3. Lateral perforation and strip perforation

Perforations of the pulp chamber wall and areas

of root may occur during access opening of the pulp chamber and during root canal instrumentation. Root perforation repair has historically been an unpredictable treatment modality with a high rate of clinical failures. But some recent developments helped in enhancing the prognosis of both surgical and non-surgical procedures. MTA is the most important of those.

Technique: If a strip or a lateral perforation is accidentally caused during instrumentation, first finish the cleaning and shaping of canal. Then irrigate the canal thoroughly with sodium hypochlorite and dry it with a paper point. The perforation can be located with the paper point. If the perforation is down at the mid to apical third, mix MTA and fill the canal with it and then spread it laterally with a spreader. The MTA will seal off the perforation. Then flood the canal with an epoxy resin cement and obturate with a single gutta-percha cone. If the perforation is closer to coronal third, first obturate the canal with gutta-percha. Then remove the gutta-percha about 2-3mm below the perforation using a piezo-reamer. Now mix MTA and fill the rest of the canal with a plugger [22].

Long term perforations with periodontal inflammation can also be successfully treated with MTA using a 'modified matrix concept'. In some cases of long term perforations, granulation tissue may have grown into the perforation. To displace this tissue and to allow the exact reconstruction of the root surface, small pieces of collagen are used. These serve as an external barrier or matrix, when pushed through the perforation. Using an application device, freshly mixed MTA is layered against the collagen until the perforation is repaired. The collagen will be resorbed and results in healing of periodontal ligament [2].

4. Furcal perforation

Furcal perforation is an unfortunate incident that can occur during root canal therapy or during post-preparation of multi-rooted teeth. Due to bacterial leakage or lack of biocompatibility of repair materials, the furcal perforation repair had a poor prognosis. But with the introduction of MTA, furcal perforation can be repaired adequately.

Technique: In case of an iatrogenic furcal perforation, there are two ways to repair it. If you can finish the RCT in one visit, then finish it first. Next remove the excess gutta-percha from the chamber and soak it for 5 min with sodium hypochlorite. Now, mix MTA and fill the pulp chamber with it. Using a moist cotton pellet plug the MTA down into perforation site and then remove the excess. Place a moist cotton pellet in the chamber to help with the setting of MTA and restore the cavity with a temporary cement. Then assess the setting of

MTA after 4 hours or in the next visit by removing temporary restoration and cotton pellet. Next, restore the cavity with amalgam or composite. If RCT cannot be done in one visit, then first seal the perforation with the MTA mixture. Remove the excess, place a moist cotton pellet over the MTA and restore the cavity with a temporary filling material. Perform RCT in the next visit [22, 15].

5. Apexification

Despite the demonstrated clinical success of calcium hydroxide apexification, there are some disadvantages of this technique. The apical closure is unpredictable, and the time necessary to achieve the final result is variable and for adults an acceptable result may never be achieved [10]. Also this requires multiple visits. MTA has been suggested as an ideal material to promote the formation of an apical barrier in a one-visit procedure [23]. The importance of this approach lies in the expedient cleaning and shaping of the root canal system, followed by its apical seal with a material that favours regeneration [18].

Technique: Isolate the tooth using rubber dam, prepare an adequate access cavity and cleanse the root canal system with copious irrigation using sodium hypochlorite. The canals require only minimum shaping. Mix the MTA powder and carry it to the apical area with the pre-fitted Dovgan carrier. It should be positioned exactly at the foramen. The thickness of the apical plug should be 3-4mm. Ultrasonic condensation (i.e., touching the plugger with an ultrasonic tip while slightly condensing the MTA) is recommended to avoid voids. Take a radiograph. If it looks appropriate, place a wet paper point in the canal in contact with MTA and then close the access cavity with a temporary cement. At the next visit assess the hardness of the apical plug. Then root canal therapy is completed [7, 12,16, 18].

6. Root end filling

MTA was introduced as a root end filling material. MTA provides a better seal than formerly used materials such as amalgam and super-EBA. Because of its superior properties and also its beneficial effects on pulpal and periodontal regeneration, it appears to be a suitable material which tightly seals the dental hard tissues from the periodontium [8]. Studies have shown that 4mm thickness of MTA is adequate for a good apical seal [9]. MTA stimulates periradicular tissue repair at the root-end situation [5].

7. Root canal filling

MTA can be used as a root canal filling materi-

al. But as it is very expensive, it is not widely used. MTA will enhance the prognosis if used as a root canal filling material in certain clinical cases like thin horizontal fracture of root [17].

A CASE REPORT

A 53 year old male patient was referred to our endodontic department for evaluation of a tooth undergoing root canal treatment. Upon clinical and radiographical examination, a perforation of size 1mm² was revealed in the disto-lingual aspect of the floor of the pulp chamber in the furcation area in relation to tooth 36. Decision was taken to rehabilitate the tooth by conventional endodontic treatment and sealing of the perforation with MTA (Pro-Root MTA, Tulsa-Dentsply, Switzerland). One month post-operative recall demonstrated no adverse symptoms to the therapy (fig.1–fig. 6).

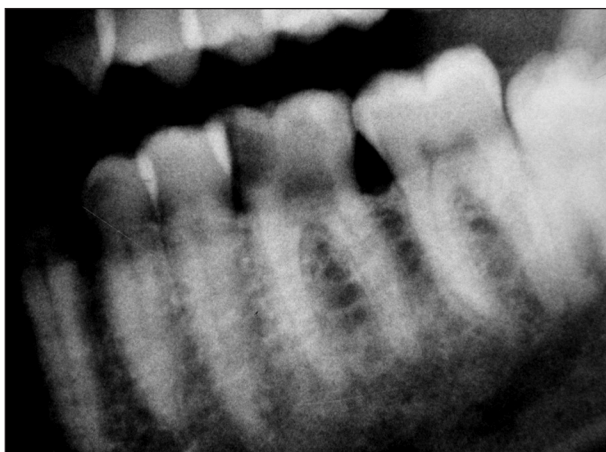

Fig. 1. Radiograph shows the presence of a perforation in the floor of the pulp chamber in the furcation area of tooth 36.

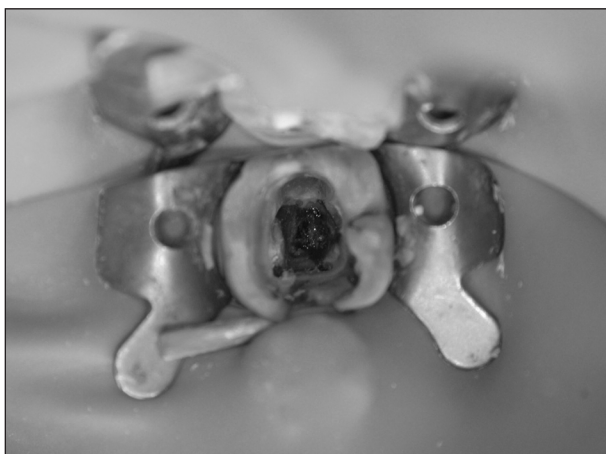


Fig. 2. Photograph shows the approximate size and the location of the perforation.

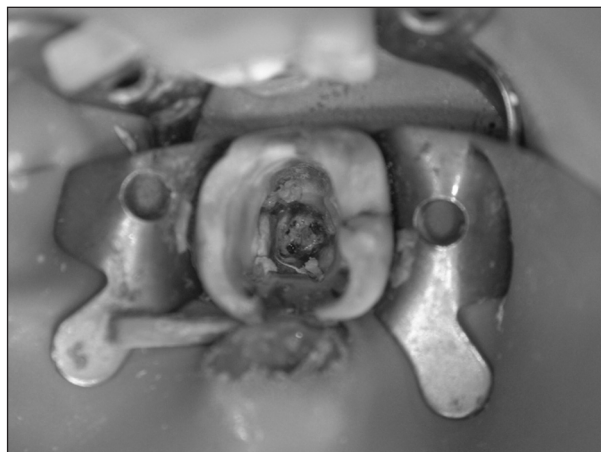


Fig. 3. After completing the obturation of the root canals, the perforation site is prepared for the placement of MTA.

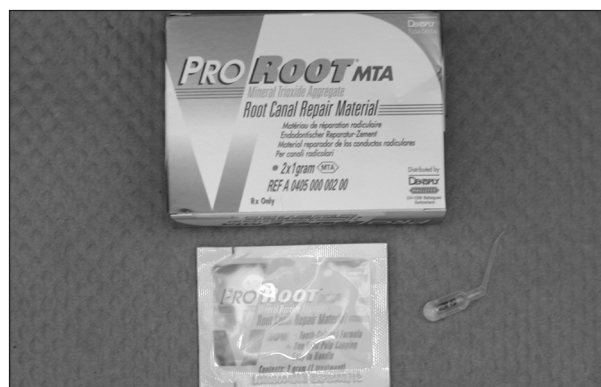


Fig. 4. Pro-Root MTA (Tulsa Dentsply, Switzerland) used for the treatment.

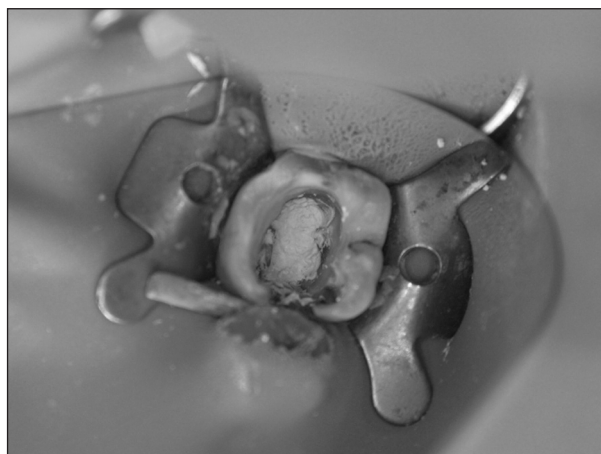


Fig. 5. MTA placed on the floor of the pulp chamber and plugged down to the perforation site.

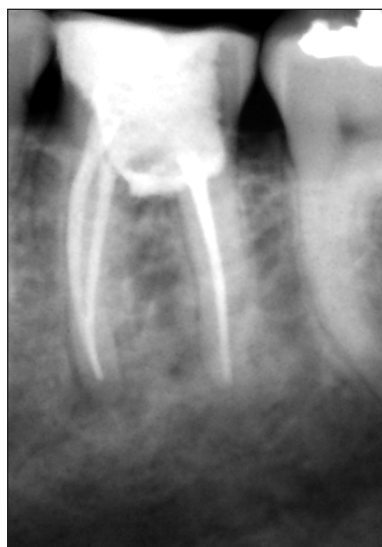

Fig. 6. Post-treatment radiograph confirming radio-opaque MTA covering the perforation site.

CONCLUSION

Mineral trioxide aggregate (MTA) is a recently developed material, which is used in modern-day dentistry for various clinical procedures, particularly in endodontics. In addition to being used as a root-end filling material, iatrogenic defects such as furcal, strip and apical perforations can be consistently repaired with MTA. Because of the simplicity in its application and the consistent success rate, MTA promises to be one of the most beneficial dental rehabilitative materials of this century. Nevertheless, more long-term follow-up studies in humans are necessary to confirm these conclusions.

REFERENCES

1. **Aeinehchi, M., Eslami, B., Ghanbariha, M., Saffar, A. S.:** MTA and calcium hydroxide as pulp-capping agents in human teeth: a preliminary report. *Int Endod J*, 36, 2003, pp. 225-231.
2. **Bargholz, C.:** Perforation repair with mineral trioxide aggregate: a modified matrix concept. *Int Endod J*, 38, 2005, pp. 59-69.
3. **Camillery, J., Montesin, F. E., Papaioannou, S., McDonald, F., PittFord, T. R.:** Biocompatibility of two commercial forms of mineral trioxide aggregate. *Int Endod J*, 37, 2004, pp. 699-704.
4. **Dentsply, Tulsa Dental.:** What is ProRoot MTA? WWW: <http://store.tulsadental.com/lit/pdfs/MTA_ProRoot_brochure.pdf>
5. **Economides, N., Pantelidou, O., Kokkas, A., Tzi-afas, D.:** Short term periradicular tissue response to MTA as root-end filling material. *Int Endod J*, 36, 2003, pp. 44-48.
6. **Glassman, G.:** Mineral trioxide aggregate: sealing the pathways of communication. *Oral Health*, July 2000.
7. **Giuliani, V., Baccetti, T., Pace, R., Pagavino, G.:** The use of MTA in teeth with necrotic pulps and open apices, *Dent Traumatol*, 18, 2002, pp. 217-221.
8. **Gondim, E. Jr., Zaia, A. A., Gomes, B. P. F. A., Ferraz, C. C. R., Teixeira, F. B., Souza-Filho, F. B.:** Investigation of marginal adaptation of root-end filling materials in root-end cavities prepared with ultrasonic tips. *Int Endod J*, 36, 2003, pp. 491-499.
9. **Lamb, E. L., Loushine, R. J., Weller, R. N., Kimbrough, W. F., Pashley, D. H.:** Effect of root resection on the apical sealing ability of mineral trioxide aggregate. *Oral Surg Oral Med Oral Pathol Oral Radiol Endod*, 95, 2003, pp. 732-735.
10. **Linsuwanont, P.:** MTA apexification combined with conventional root canal retreatment. *Aust Endod J*, 29, 2003, pp. 45-49.
11. **Masuda, Y. M., Wang, X., Hossain, M., Unno, A., Jayawardena, J. A., Saito, K., Nakamura, Y., Matsumoto, K.:** Evaluation of biocompatibility of MTA with an improved rabbit ear chamber. *J Oral Rehabil*, 32, 2005, pp. 145-150.
12. **Maroto, M., Barbería, E., Planells, P., Vera, V.:** Treatment of a non-vital immature incisor with mineral trioxide aggregate (MTA). *Dent Traumatol*, 19, 2003, pp. 165-169.
13. **Nahmias, Y., Berry, P.:** Mineral trioxide aggregate and its uses. WWW: <http://www.endoweb.com/dentist/den_frme.htm> 2005.
14. **Patel, R., Cohenca, N.:** Maturogenesis of a cariously exposed immature permanent tooth using MTA for direct pulp capping: a case report. *Dent Traumatol*, 22, 2006, pp. 328-33.
15. **Pitt Ford, T. R., Torabinejad, M., McKendry, D. J., Chan-Ui Hong, Kariawasam, S. P.:** Use of mineral trioxide aggregate for repair of furcal perforations. *Oral Surg Oral Med Oral Pathol Oral Radiol Endod*, 79, 1995, pp. 756-763.
16. **Schwartz, R.S., Mauger, M., Clement, D. J., Walker, W. A.:** Mineral trioxide aggregate: a new material for endodontics. *J Am Dent Assoc*, 130, 1999, pp. 967-975.
17. **Stefan-loan Straful, Benta, A.:** Simultaneous tooth displacement and horizontal mid-root fracture treated by re-placement and root-MTA. A report. *Int Poster J*, 6, 2004, poster 237.
18. **Steinig, T. H., Regan, J. D., Gutmann, J. L.:** The use and predictable placement of Mineral Trioxide Aggregate in one-visit apexification cases. *Aust Endod J*, 29, 2003, pp. 34-42.
19. **Torabinejad, M., Hong, C. U., McDonald, F., Pitt Ford, T. R.:** Physical and chemical properties of a new root-end filling material. *J Endod*, 21, 1995, pp. 349-353.
20. **Torabinejad, M., Hong, C. U., Pitt Ford, T. R., Kettering, J. D.:** Antibacterial effects of some root-end filling materials. *J Endod*, 21, 1995, pp. 403-406.
21. **Tziafas, D., Pantelidou, O., Alvanou, A., Belibasakis, G., Papadimitriou, S.:** The dentinogenic effect of MTA in short-term capping experiments. *International Endodontic Journal*, 35, 2002, pp. 245-254.
22. **Young Bui.:** Mineral trioxide aggregate. WWW: <<http://www.endomail.com/articles/yb10mta.html>> 2003 nov-dec.
23. **Witherspoon, D. E., Ham, K.:** One-visit apexification: technique for inducing root-end barrier formation in apical closures. *Pract Proced Aesthet Dent*, 13, 2001, pp. 455-60; quiz 462.

*Dr. Sujith Sukumar, BDS
Stomatologická klinika LF UK a FN
Sokolská 581
500 05 Hradec Králové
e-mail: docsujith@gmail.com*